

Thrombus Aspiration during Percutaneous coronary intervention in Acute myocardial infarction Study (TAPAS)

Mortality and reinfarction at 1 year

F. Zijlstra, MD PhD

Thoraxcenter

University Medical Center Groningen,

The Netherlands



Presenter Disclosure Information

Disclosure Information...

The following relationships exist related to this presentation:

Tone Svilaas

No disclosures

Pieter J. Vlaar

No disclosures

Iwan C. van der Horst

No disclosures

Gilles F.H. Diercks

No disclosures

Bart J.G.L. de Smet

No disclosures

Ad F.M. van den Heuvel

No disclosures

Rutger L. Anthonio

No disclosures

Gillian A. Jessurun

No disclosures

Eng-Shiong Tan

No disclosures

Albert J.H. Suurmeijer

No disclosures

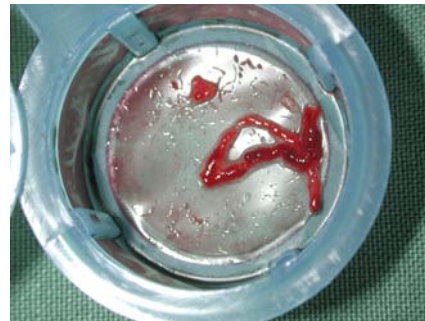
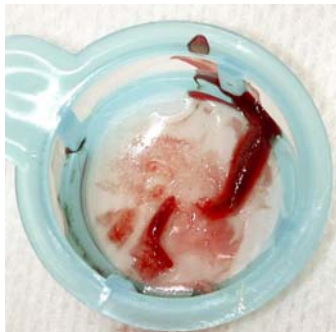
Felix Zijlstra

No disclosures



TAPAS: Background

- Myocardial perfusion after primary PCI determines clinical outcome
- Embolization of atherothrombotic material plays a crucial role in microvascular obstruction and impaired myocardial perfusion
- Previous trials have shown the feasibility of thrombus aspiration during primary PCI



TAPAS: Methods (1)

- Single center, prospective, randomized
- Consecutive patients with STEMI
- Primary endpoint
 - Myocardial blush grade (core lab)
- Secondary endpoints
 - ST-segment elevation resolution
 - 30 day death and death / reinfarction
 - 1 year death and death / reinfarction

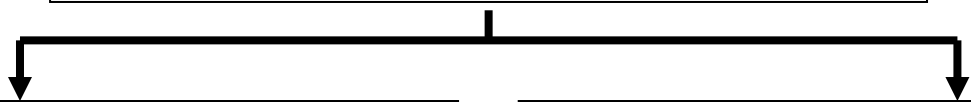


TAPAS: Methods (2)

- Randomization before angiography to thrombus aspiration or conventional PCI
- Exclusion criteria
 - Rescue PCI after thrombolysis
 - Life expectancy < 6 months
- Standard treatment
 - Heparin, aspirin, clopidogrel, abciximab
- Intention to treat analysis



1071 STEMI patients randomized



535 were assigned to thrombus aspiration

536 were assigned to conventional PCI



33 did not undergo PCI
502 underwent primary PCI
295 underwent TA followed by direct stenting
153 underwent TA with additional balloon dilation
54 had crossover to conventional PCI

33 did not undergo PCI
503 underwent primary PCI
485 underwent balloon dilation followed by stenting
12 underwent conventional PCI with additional TA
6 had crossover to TA



530 complete follow-up at 1 year

530 complete follow-up at 1 year



Baseline clinical characteristics

Characteristic	Thrombus aspiration N = 535	Conventional N = 536
Age, years	63±13	63±13
Male gender	68%	73%
Body mass index	27±4	27±4
Hypertension	33%	37%
Family history	46%	45%
Diabetes	11%	13%
Hypercholesterolemia	24%	27%
Current smoking	46%	48%
Previous MI	10%	11%
Total ischemic time (min)	190 (110-270)	185 (107-263)

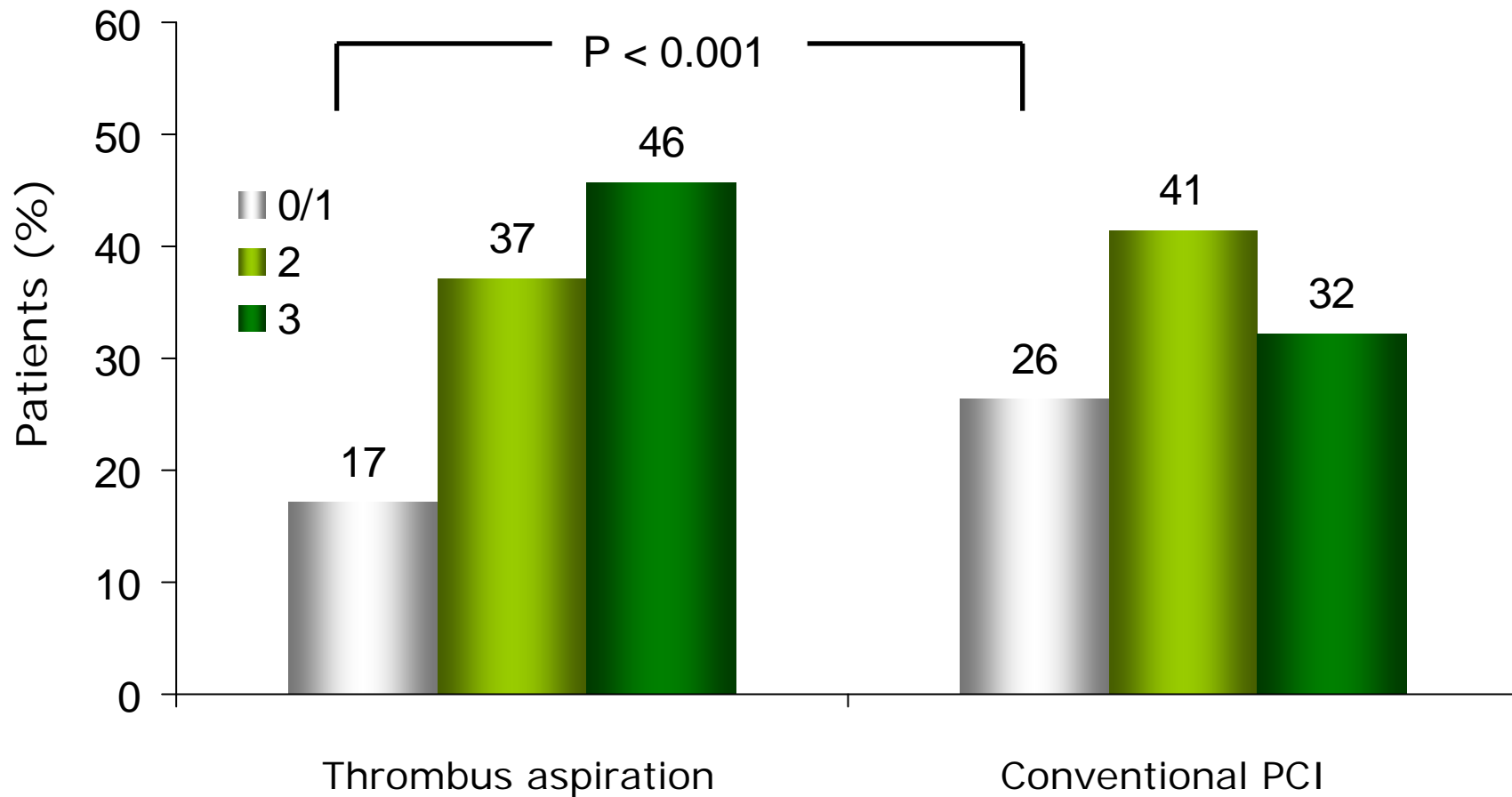


Baseline angiographic characteristics

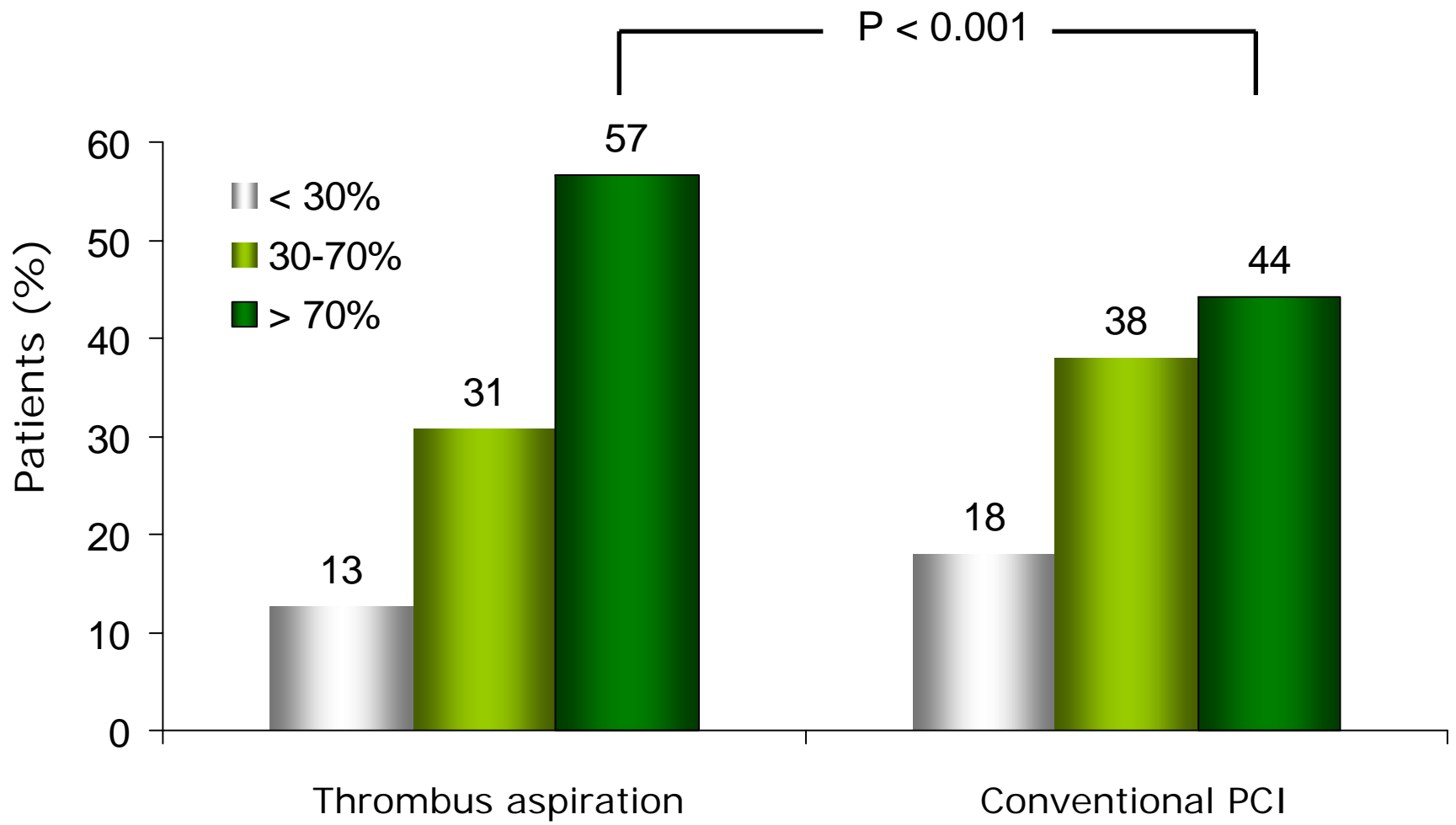
Characteristic	Thrombus aspiration N = 535	Conventional N = 536
Infarct related vessel		
LAD	43%	43%
LCX	18%	15%
RCA	37%	40%
Multivessel disease	66%	69%
TIMI flow grade		
0 or 1	55%	60%
2	19%	16%
3	26%	25%
Thrombus	49%	46%



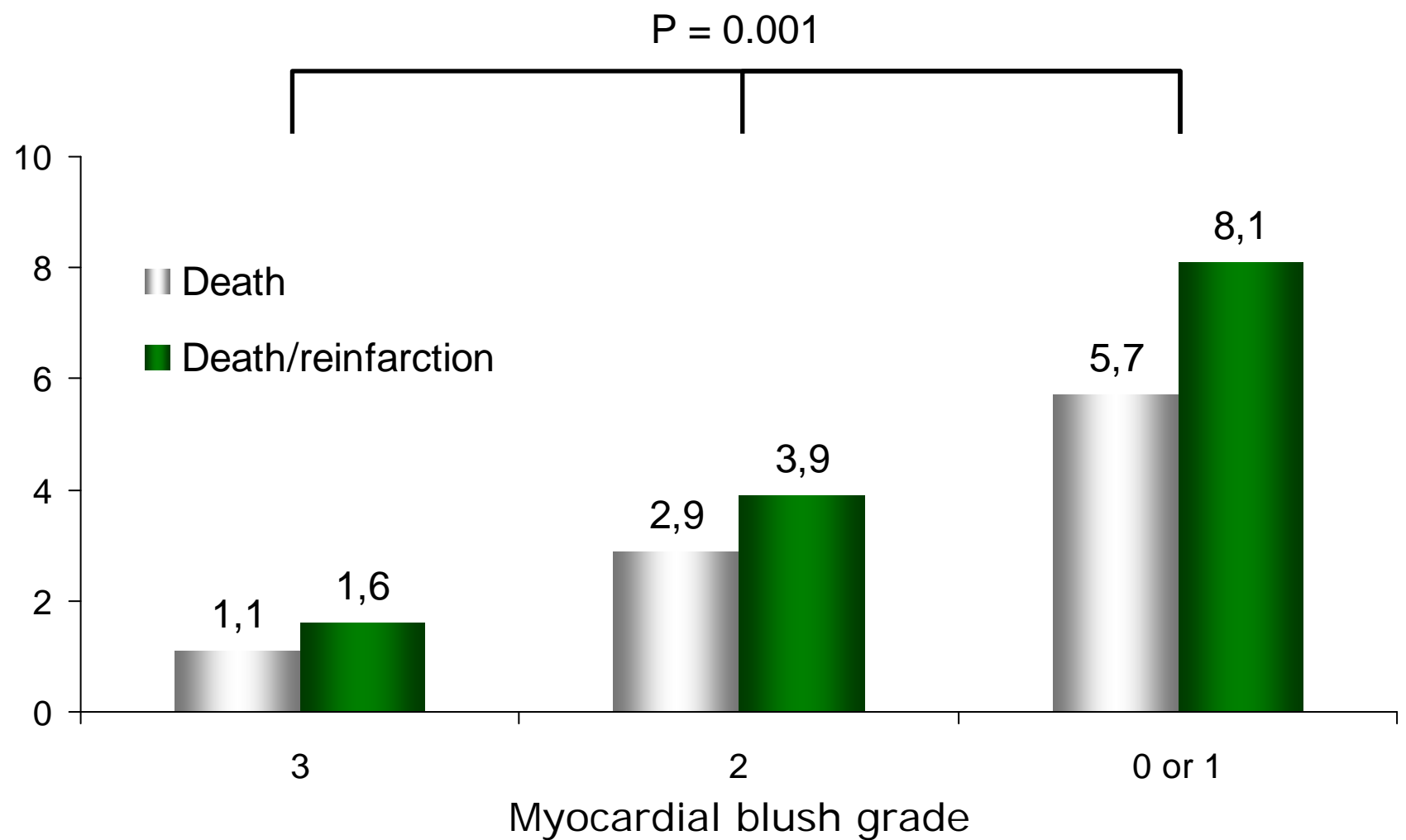
Primary endpoint: Myocardial blush grade



ST-segment elevation resolution

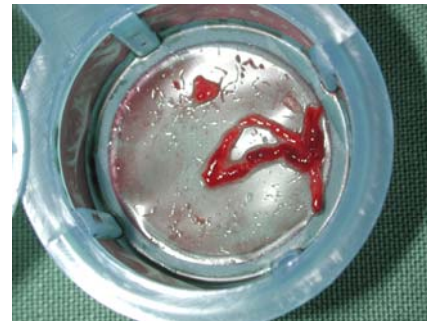
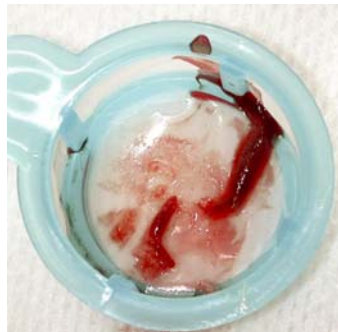


Myocardial blush grade and death or death/reinfarction at 30 days



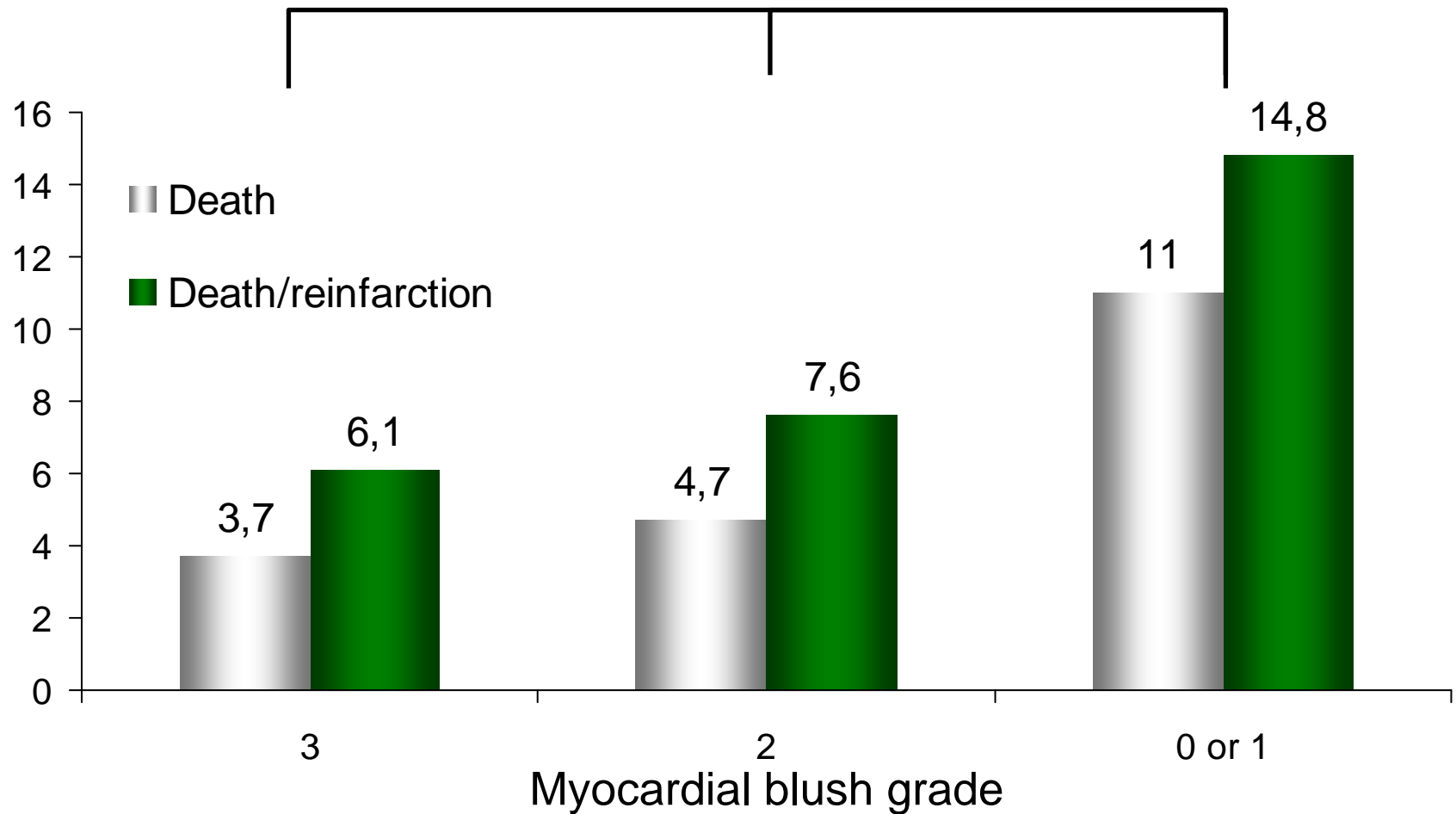
TAPAS: Summary of findings at 30 days

- Thrombus aspiration results in improved myocardial reperfusion
- Myocardial blush grade predicts 30 day rates of death and reinfarction
- Does improved myocardial reperfusion translate into clinical benefit at 1 year?

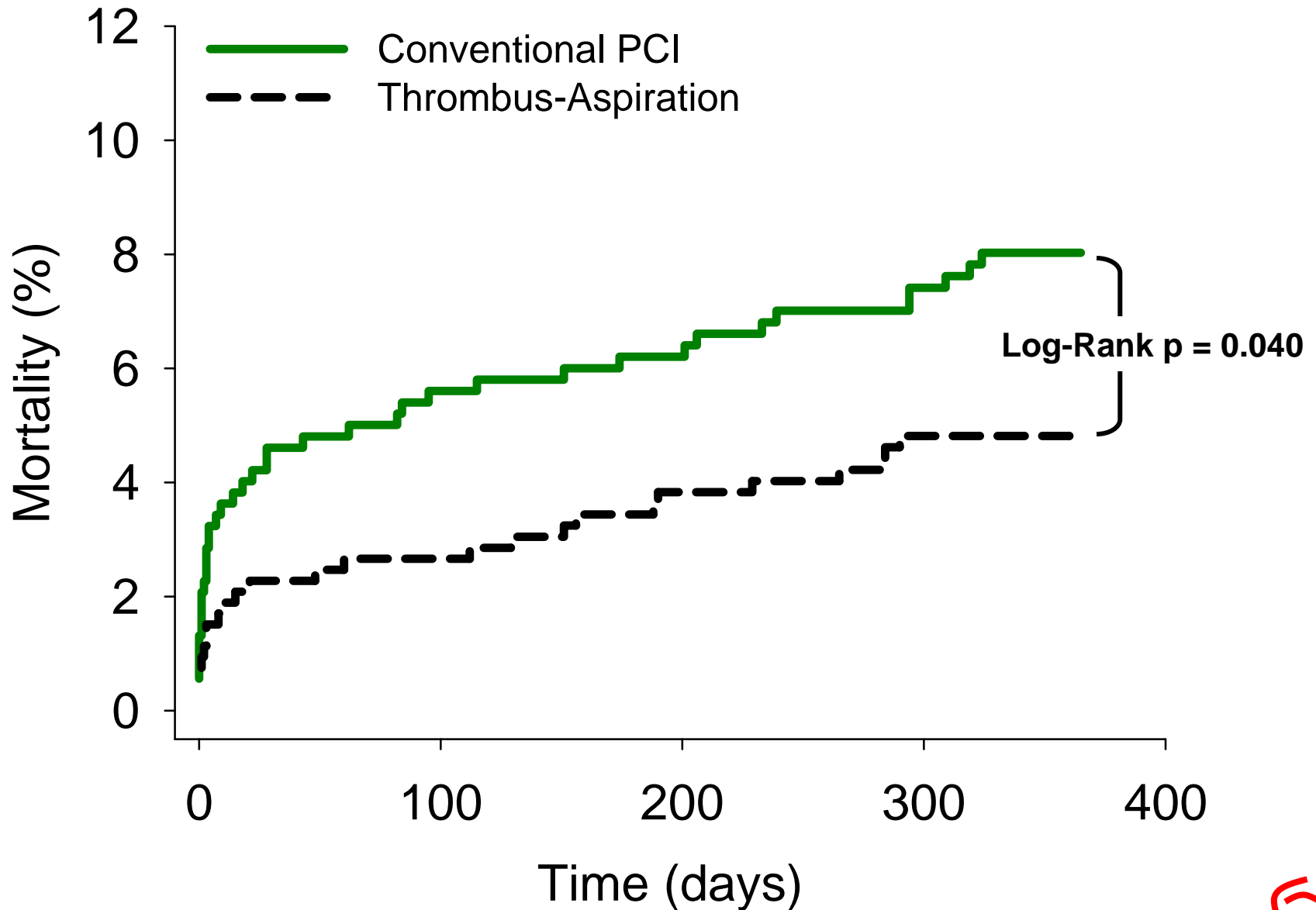


TAPAS one year outcome: Myocardial blush grade and death or death/reinfarction at 1 year

P = 0.001



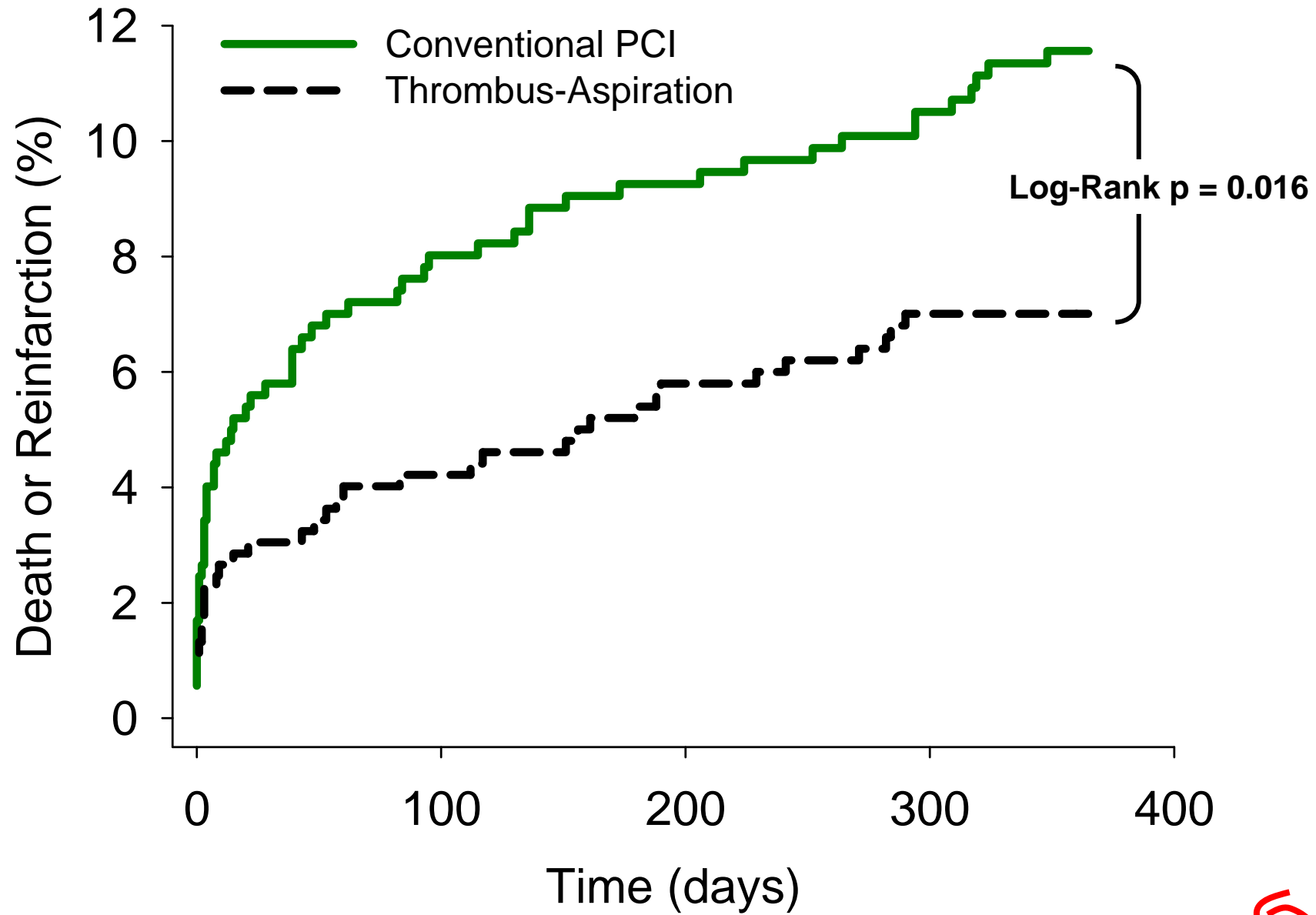
Mortality at 1 year



*Unpublished results



Mortality or non-fatal ReMI at 1 year



*Unpublished results



TAPAS: Mortality and reinfarction at 1 year

- Myocardial blush grade predicts clinical outcome at 1 year
- Thrombus aspiration results in a lower mortality and combined mortality and non-fatal reinfarction at 1 year

